



RESENTING CLINICAL SIGNS

History: Recheck degenerative valve disease. Also previously diagnosed with tracheal/mainstem bronchial collapse, tracheobronchitis, and a collapsing event. Receiving pimobendan 0.625 mg BID theophylline, tetra/neo/pred.

DATE

5/11/22

ECHOCARDIOGRAPHIC FINDINGS

2D, M-mode, and Doppler study. This exam is compared to the one performed 10/13/21.

PERFORMED BY:

Dr. Brian Barnes

INTERPRETED BY

Keith Blass, DVM,
MS, DACVIM
(Cardiology)

There is mild left atrial dilation. The mitral valve leaflets are thickened and exhibit systolic prolapse. A mild to moderate jet of mitral regurgitation is present. Left ventricular dimensions are normal. Left ventricular systolic function is normal. The aorta and aortic valve are normal. Right atrial and right ventricular dimensions are normal. The tricuspid valve leaflets are mildly thickened, and a mild jet of tricuspid regurgitation is present. TR velocity does not suggest the presence of pulmonary hypertension. The pulmonary artery and pulmonic valve appear normal, though trace pulmonic insufficiency is present. No pericardial effusion or cardiac masses are seen.

ECG during echo: Sinus/sinus arrhythmia

PATIENT

Lexie Macauley

LA - 21.5 mm (prev. 23.6 mm)
LVIDd - 17.9 mm (prev. 22.0 mm)
LVIDs - 10.9 mm (prev. 11.8 mm)
FS - 39% (prev. 46%)
LVOT - 1.05 m/s (prev. 1.04 m/s)
RVOT - 0.78 m/s (prev. 0.80 m/s)
TR - 235 m/s (prev. 2.34 m/s)

SPECIES

Canine

ASSESSMENT/RECOMMENDATIONS

Degenerative mitral and tricuspid valve disease

BREED

Pomeranian

This examination demonstrates no progression of Lexie's valvular diseases over the past 7 months. As such, her diseases still appear to be well-compensated, and it's unlikely that they are advanced enough to be the cause of her previous collapsing episode. It's likely that Lexie's collapsing episode was vasovagal in origin, though an intermittent arrhythmia cannot be definitively ruled out as a possible cause.

SEX

FS

No change in therapy is recommended based on this exam.

AGE

11 y

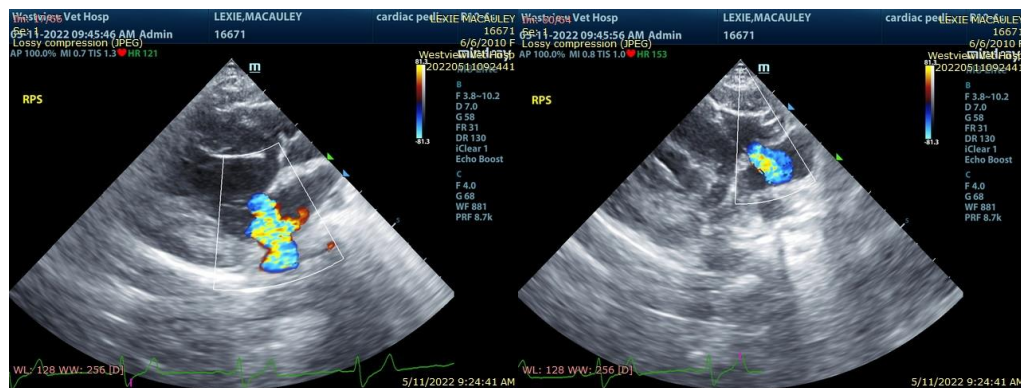
A recheck (X-ray +/- echocardiogram) is recommended in 9 months, sooner if new clinical signs compatible with cardiac dysfunction develop.

WEIGHT

2.75 kg

HOSPITAL NAME

Westview VH



REFERRING VET

Dr. Barnes



DATE

5/11/22

The information and recommendations provided are based on the images presented by the referring veterinarian. No evaluation can be communicated regarding pathology that was not visible in the image/video clips provided.

PERFORMED BY:

Thank you for this referral. If the clinical or image interpretation does not parallel your findings or if I can be of any further assistance please contact me.

Dr. Brian Barnes

INTERPRETED BY

Keith Blass, DVM, MS, DACVIM (Cardiology)
KeithBlass@gmail.com
631-804-5754

Keith Blass, DVM,
MS, DACVIM
(Cardiology)

PATIENT

Lexie Macauley

SPECIES

Canine

BREED

Pomeranian

SEX

FS

AGE

11 y

WEIGHT

2.75 kg

HOSPITAL NAME

Westview VH

REFERRING VET

Dr. Barnes